ISSN 2598-3180 (Online)
JOURNAL OF MIDWIFERY
Research and Practice
Accredited by SINTA 4th

Article

Atypical presentation of leiomyomas: A case series report

Partha Sarathi Mitra[1], Puja Kumari[2], Dristy Majhi[3], Paramita Saha[4], Amity Saha[5], Ramakanta Mazumder[6], Priyanka Sanyal[7], Tapan Kumar Naskar[8]

[1,2,4,5,6,7,8]Department of Obstetrics and Gynaecology, Medical College, Kolkata

SUBMISSION TRACK

Recieved: February 26, 2025
Final Revision: June 02, 2025
Available Online: June 30, 2025

KEYWORDS

Atypical Fibroids, Cervical Fibroid, Cornual Fibroid, Broad Ligament Fibroid

CORRESPONDENCE

Phone: 8250259127
E-mail: amitys.93@gmail.com

A B S T R A C T

Fibroids are the most common benign smooth muscle tumours of uterus. Some patients are asymptomatic whereas symptomatic patients may present with heavy menstrual bleeding, dysmenorrhoea and pressure symptoms. Case report: Six Atypical fibroid cases have been reported in this case series report because of their rarity, diagnostic dilemma and difficulty in surgical approach supplemented by photographical evidence against each case. In case of Atypical fibroids, symptoms depend on the site of involvement and they may mimic other pelvic organ involvement like ovarian malignancy. Fibroids are mainly diagnosed by ultrasonography (USG) and magnetic resonance imaging (MRI) but may be difficult because of its unusual findings on USG and MRI. Patients can be managed either conservatively or surgically depending on their response. Surgical options include conservative surgery like Myomectomy or Hysterectomy, which can be done by open surgery or by minimally invasive surgery (MIS). The case series report may highlight on surgeons' approach in case of atypical fibroids.

Attribution-NonCommercial 4.0 International. Some rights reserved

I. INTRODUCTION

Fibroids are very common benign monoclonal tumours of the smooth muscle cells of the myometrium. They contain large aggregation of extra cellular matrix composed of collagen, elastin, fibronectin and proteoglycan (Leppert, et al, 2006). Fibroids are an important health concern because they are the most frequent indication for hysterectomy (Whiteman, et al, 2008). They are mostly asymptomatic or present with heavy menstrual bleeding (Berek and Novak's). Big sized fibroids may lead to pressure symptoms of bladder and bowel. Fibroids are mainly seen in reproductive age group and regress after menopause. They are managed by both ways medically and surgically depending on the symptoms and size. Patients are usually monitored for a period of 72 months for residual or recurrence of fibroid (Kalogiannidis, 2016). Fibroids which are not of uterine origin are rare. They can be of many varieties like cervical fibroid, broad ligament fibroid, cornual fibroid etc. Their symptoms mainly depend on the site of involvement. Huge fibroids may present with urinary symptoms, chronic pelvic pain, obstructive uropathy which may lead to hydroureter and hydronephrosis (Vyas, et al, 2023). Unusual manifestation may lead to bladder bowel dysfunction and compressive neuropathy (Su, et al, 2012). Mild or moderately symptomatic women require follow ups perhaps indefinitely(Berek and Novak's). Surgical treatment options include myomectomy either open or MIS, laparoscopic radiofrequency ablation, endometrial ablation and Hysterectomy either abdominal, vaginal or MIS (Berek and Novak's).

II. METHODS

Case series report: We hereby report six cases of atypical fibroid, their surgical management and histopathological examination report during the period of August 2024 to January 2025 at Medical College Kolkata, West Bengal

III. RESULT

Case 1

A patient, 43 yrs, multiparous woman presented with a huge, painless, abdominal swelling for past 10 months, gradually increasing in size with frequent urination, acute urinary retention and difficulty emptying the bladder for the past 4 months. Her menstruation used to continue for 7-10 days, irregular in cycle with normal flow pattern without passage of clots or pain. There was no family history of leiomyoma. On examination, a firm to hard mass, 32 weeks in size filling the abdominal cavity, immobile, obscured margin, smooth surface, firm to hard in consistency was felt per abdominally. On per vaginal examination, a hard mass was felt through pouch of Douglas (POD) which was encroaching bilateral fornices. Cervix could not be identified, uterus could not be digitally palpated. Her general examination and other systemic examination were within normal limits. On ultrasonography (USG), a hugely bulky uterus of size 23 x 19 x 19 cm with multiple fibroids, largest being 16.85 x 17.84 cm, bilateral hydronephrosis left more than right was noted. Bilateral ovaries were normal. There was neither any adnexal mass lesion nor any collection in POD with no ascites. An exploratory laparotomy was done and a huge mass of 24 x 20 cm size found occupying the entire peritoneal cavity. Uterus was identified sitting over the huge fibroid mass as described as *lantern on the dome of St. Paul's cathedral* fig-1. Myomectomy was contemplated to remove approximate (approx.) 22 x 20 cm cervical fibroid and 2 x 4 cm fundal fibroid fig 1, followed by total abdominal hysterectomy & bilateral salpingo-oopherectomy (TAH BSO). On histopathology examination diagnosis of cervical fibroid was confirmed fig-1.

Case 2

A 51 year old Para 5+1(P 5+1), menopause attained 10 year back presented with vaginal bleeding since 2 months, pelvic pain and frequent urination since 5-6 months. On abdominal examination – abdomino pelvic lump was found which was 24-28 weeks in size, variegated in consistency and with restricted mobility. On abdominovaginal examination an abdominopelvic mass of 28 week

in size was found, with fornices and POD full and bulging with irregular outline of cervix. Tumour markers such as CA 19.9 was 90, CA125 was 4496, ALP was 487 and RMI was 13488. On USG uterus was bulky with a heterogeneous right adnexal space occupying lesion (SOL) of 20.8*13.8cm size, extending up to left adnexa and on MRI a complex right ovarian cyst of 14.4*19cm size was detected. The lesion was difficult to distinguish from degenerated exophytic fundal fibroid. Exploratory laparotomy was done to find a large SOL of size 14*16 cm, originating from right broad ligament likely to be degenerated fibroid with bilateral ovaries found healthy fig2. At first myomectomy was done to define exact anatomy of uterus, fallopian tube, ovary and other pelvic organs. After myomectomy, TAH BSO was done. On histopathological examination diagnosis of fibroid was confirmed fig-2.

Case 3

A 27 year old woman presented with pelvic pain and infertility since 9 months. On per abdominal examination uterus was found to be 16weeks in size. Laparoscopic assisted hysterectomy was planned. During laparoscopy size of the uterus was of 16weeks and an intramural fibroid located at left cornu of uterus fig3. Laparoscopic hysterectomy was done and vault repaired from vaginal end and specimen was sent for histopathological examination. Her post operative recovery was fast and without any complication in comparison to open surgeries.

Case 4

A 51 year old woman presented with pain abdomen since 1 month. On per abdominal examination an abdomino pelvic mass was detected which occupied lower abdominal area. On contrast enhanced computed tomography (CECT) a large hypodense lesion was seen in pelvis displacing loop of intestine laterally which was possibly an exophytic pedunculated fibroid along with bulky cystic left ovary and mild ascites. During TAH BSO after opening the abdominal cavity, a large pelvic SOL of approx. 13*9*7 cm in size occupied abdominopelvic cavity which was removed along with uterus, tubes and ovaries. On gross examination there was a small fibroid of approx. 1.5 cm in size in the body of the uterus and the specimen was sent for histopathological examination fig 4. Fibro-thecoma of ovary and leiomyoma of uterus were confirmed on histopathological report.

Case 5

A woman, 40 years of age, presented with heavy menstrual bleeding, acute urinary retention and urinary tract infections. On per abdominal examination uterus was found to be 28 weeks of size and a supra pubic soft cystic lump was felt. On USG a large fibromyoma of uterus was diagnosed. TAH was planned. Abdominal cavity was opened. A large uterus of 28 weeks size containing a huge degenerated fibroid was found occupying the whole abdomino pelvic cavity fig 5. After TAH we found thick and purulent material coming out from the uterine cavity and cervix. Specimen and pus were sent for histopathological and microbiological examination respectively.

Case 6

A 48years woman, P3+0 presented with complain of heavy menstrual bleeding since 1 month and abdominal pain since 1 year with irregular menstrual history. On per abdominal examination, a 28 weeks size uterus and abdomino pelvic mass, well marginated, firm in consistency, with restricted mobility was found. On per vaginal examination a huge cervical fibroid was found on posterior wall. On USG, uterus was found to be bulky with multiple fibroids noted in anterior and posterior myometrial wall, largest one of size 9.1*8.2cm in posterior wall of lower segment. TAH BSO was planned. Abdominal cavity was opened to find a huge cervical fibroid in the midline and multiple fibroids in the right sided broad ligament, the extension of which could not be delineated. Meticulous dissection was done to define the extension of broad ligament fibroid and to avoid inadvertent injury to associated vital structures. Cervical fibroid was of size approx. 10*9cm. Uterus, cervix with fibroid was dissected out and vault was repaired with absorbable suture. Right

sided internal iliac artery ligation was done to control diffuse pelvic haemorrhage. Dissected specimen was sent for histopathological examination and diagnosis of both cervical and broad ligament fibroids were confirmed fig-6.

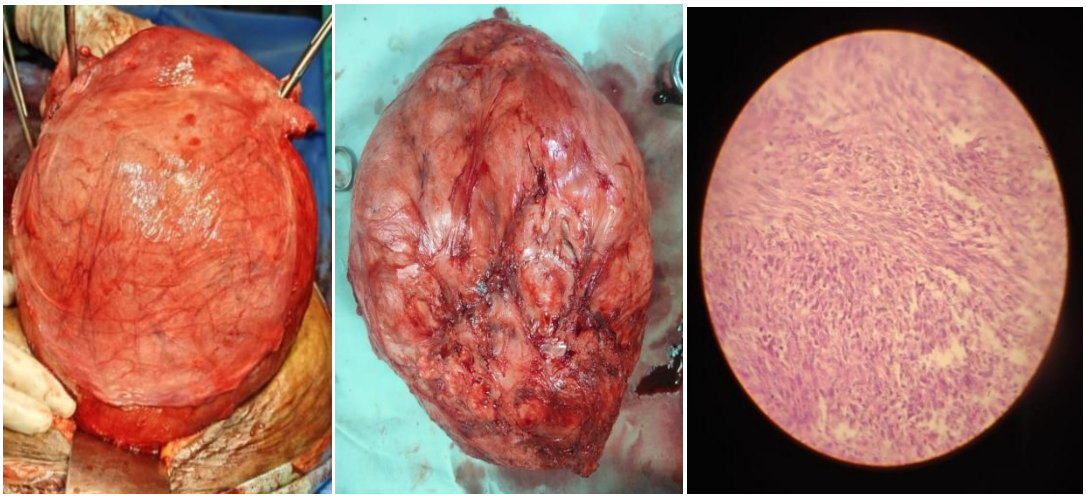

1a 1b 1c

Fig. 1- Lantern on the dome of St Paul's cathedral (cervical fibroid)

1a- Cervical fibroid
1b- Myomectomy specimen
1c- Smooth muscle on histopathological report
Surgery on 05.11.2024. Report revealed on 12.11.2024 after informed consent.

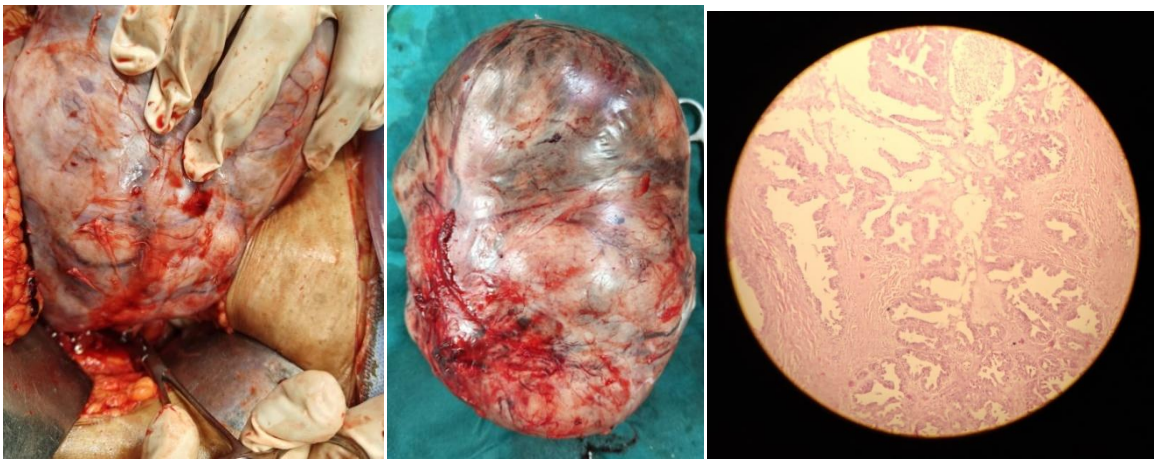

2a 2b 2c

Fig. 2- Broad ligament fibroid

2a- Right sided broad ligament fibroid
2b- Myomectomy specimen
2c- Slide no-8171
Surgery done on 26.11.2024. Report revealed on 21.12.2024 after informed consent.

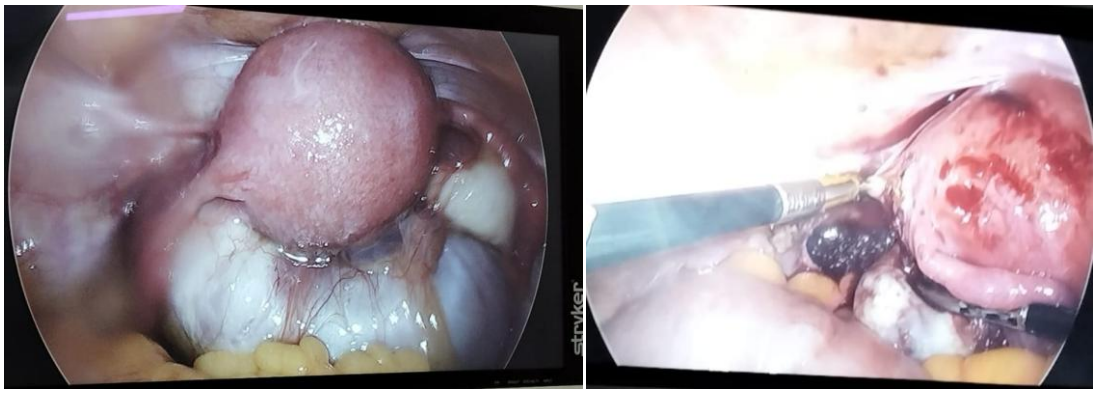

3a 3b

Fig. 3- Cornual fibroid

3a,3b- Cornual fibroid on laparoscopic view
Surgery done on 19.08.2024 and specimen revealed after informed consent

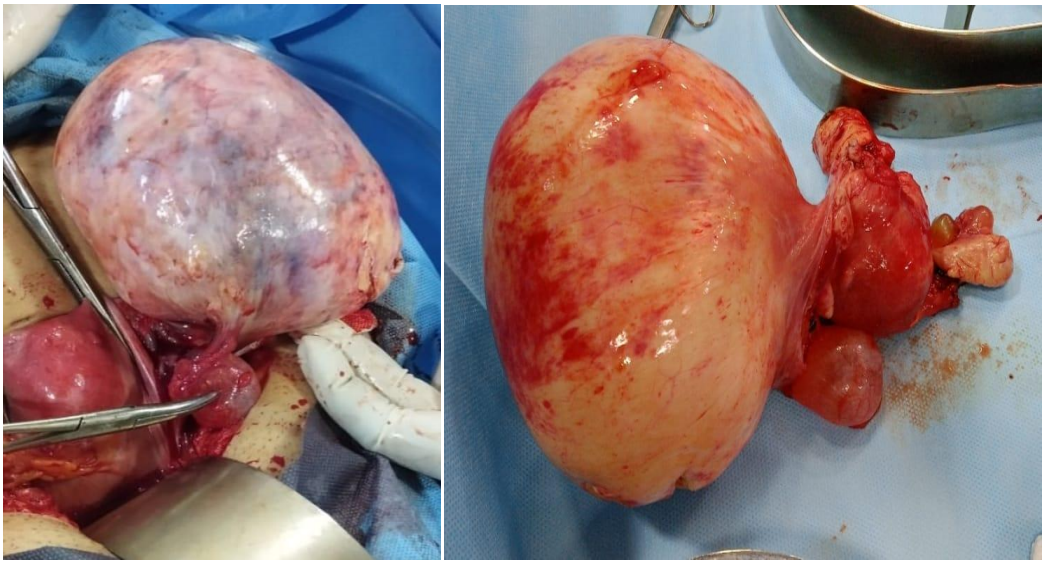

4a 4b

Fig. 4- Fibrothecoma of left ovary with adenomyotic changes in uterus

4a- Fibrothecoma of left ovary with adenomyotic changes of uterus
4b- Specimen of left ovary
Surgery done on 18.11.2024. Report revealed on 21.11.2024 after informed consent.

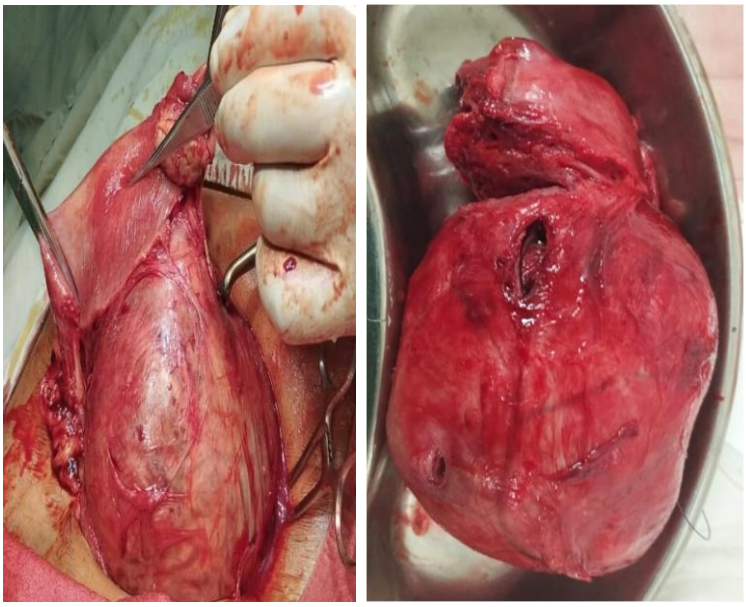

5a 5b

Fig. 5- Huge fibroid mass with degenerative changes

5a- Mass involved left abdominopelvic cavity
5b- Huge fibroid with degeneration
Surgery done and report revealed after informed consent

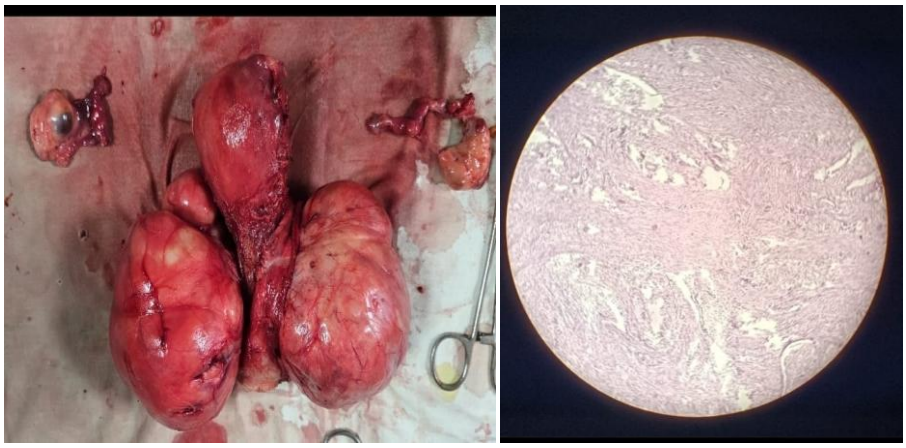

6a 6b

Fig. 6- Cervical fibroid

6a- Cervical fibroid
6b-Histopathological slide
Surgery done on 07.01.2025. Report revealed on 27.01.2025 after informed consent.

IV. DISCUSSION

Fibroids or myomas or leiomyomas are the most common uterine tumors usually seen in reproductive age group of females. Incidence of myomas is as high as 50%. Mostly small fibroids are asymptomatic but some of them may present with a variety of symptoms. Menstrual symptoms are most common. The patients may have dysmenorrhea, menorrhagia, polymenorrhea, infertility, and lower abdominal pain.

As in case 1 and case 6 , cervical fibroid was considered an atypical presentation because, unlike most uterine fibroids, it grew within the cervix, causing urinary symptoms like frequent urination or difficulty emptying the bladder, rather than the typical heavy menstrual bleeding or pelvic pain associated with fibroids in the uterine body, making diagnosis more challenging and potentially leading to misinterpretation as a bladder or pelvic floor disease fig. 1 and fig. 6 respectively. Ninety-five percent of leiomyomas are found in the uterine corpus; just one to two percent are seen in the cervical region (Vitale, et al, 2017). These tumours are estrogen-dependent. The cervical fibroid can arise either from the supravaginal or vaginal portion of the cervix. It may originate from the anterior, posterior, central, or lateral aspects. Cervical fibroid is classified as type 8 in the FIGO classification of uterine fibroid (Laughlin-Tommaso, et al, 2017). Cervical fibroid may be present with varied symptoms like irregular vaginal bleeding, heavy menstrual bleeding, dysmenorrhea, chronic pelvic pain, and pressure effects causing disturbance in bladder and bowel habits. Cervical leiomyomas can change the shape of the cervix and cause its lengthening and effacement. It can also cause the uterus to push upwards or the bladder to be drawn up when its size increase, which may cause urinary tract infections. Cervical fibroid may have an impact on a woman's obstetric outcome like infertility, abortion, early discomfort, more surgical intervention, and a protracted postpartum recovery. Sometimes it is difficult to reach the diagnosis of cervical fibroid as it mimics various other gynaecological conditions or because of some atypical presentation like polypoidal vaginal mass, incarcerated procidentia, chronic uterine inversion, uterocervical descent, ovarian mass, acute urinary retention, or cervical carcinoma (IJOGR, 2024).

Large cervical fibroids give a typical appearance known as “Lantern on St. Paul’s dome” where the small sized normal uterus sits on top of the cervical fibroid mimicking the Lantern on the dome of famous St. Paul’s Cathedral of Russia (Acharya, 2020). This has been seen in case 1 fig. 1. Anterior cervical fibroids exert pressure effects on the bladder causing urinary retention or urinary frequency due to pressure over the uterovesical junction. Posterior cervical fibroids press over the rectum thereby flattening it and cause constipation or painful defecation while the lateral cervical fibroids grow into the broad ligament and compress the ureters leading to hydroureters (Mendiratta, 2017).

As in case 2, a broad ligament fibroid was considered an atypical presentation of a uterine fibroid because it grew outside the uterine wall, within the broad ligament, producing symptoms like pelvic pain, pressure on the bladder or bowel, and it was difficult to diagnose due to its unusual location, potentially mimicking other pelvic masses like an ovarian cyst, making it an atypical presentation compared to more common uterine fibroid locations fig. 2. The most common extra uterine site of fibroid is broad ligament with an incidence of <1% and other rare locations are round ligament, ovarian ligament, and ovaries[14]. There are two types of broad ligament fibroids; false broad ligament fibroid that grows into the broad ligament from the uterus, and true broad ligament fibroid that arises from subperitoneal connective tissue of the ligament. In our case, this was a true broad ligament leiomyoma fig. 2. Extrauterine fibroid can be among the differential diagnosis of uterine fibroid, others being broad ligament fibroid, solid ovarian mass, pedunculated subserosal fibroid or lymphadenopathy. It can be difficult to make diagnosis using ultrasonography especially when the fibroids are big and displace adjacent structures. Diagnostic options include imaging modalities such as ultrasonography (USG), computed tomography (CT) or magnetic

resonance imaging (MRI). MRI has the highest sensitivity and can describe secondary changes like degenerations, calcifications, or necrosis. This can also assist in planning out the surgery. However, the final diagnosis is made by histology. Surgery is the mainstay for the management of symptomatic leiomyomas. Due to the size and location, sometimes surgery is challenging due to the proximity of nearby pelvic and abdominal structures. Laparoscopic surgery can be an option, but surgeons should note that the fibroids can be much larger than the initial appearance because the pelvis and retroperitoneal space can accommodate as a reservoir and needs careful hemostasis during dissection as they can be very vascularized and in close relations to nearby vital structures (ureters, internal iliacs, and nerves etc.). Uterine artery embolization may have little or no effect because the mass may not rely on the uterus for its blood supply as it is located outside the uterus (Song, et al, 2018). If the setting allows, robot assisted laparoscopic myomectomy (RALM) can be an option.

As in case 3, a cornual fibroid was considered an atypical presentation of uterine fibroids because it was located in the upper left corner of the uterus, near the fallopian tube opening, leading to unique symptoms like infertility issues, pelvic pain, and sometimes complications with pregnancy due to its unusual position, unlike more common locations within the uterine wall fig. 3.

As in case 4, uterine leiomyoma and fibrothecoma of ovary can coexist fig. 4. While both uterine fibroid and ovarian fibrothecoma are benign tumors composed primarily of fibrous tissue, there is no direct, established association between the two. One does not increase the incidence of the other; however, they share some similarities in presentation and can sometimes be confused due to their similar imaging characteristics, especially if the ovarian fibrothecoma is large and located near the uterus, leading to potential misdiagnosis on imaging alone. Ovarian fibrothecoma is the most common benign solid tumor of the ovary (PMC, 2018). It can present with an abdominal mass or torsion but is commonly asymptomatic. The presence of an intrapelvic solid tumour can be difficult to differentiate from uterine leiomyomas, other solid ovarian tumours or ovarian malignancy. Ovarian fibrothecoma can be associated with raised tumour marker levels and ascites, and this could lead to a mistaken preoperative diagnosis of ovarian malignancy. Conversely, studies have also shown that approximately 30%–40% of patients with ovarian fibrothecoma were misdiagnosed preoperatively as uterine leiomyomas (Leung and Yuen, 2006). The importance of preoperative counselling in the presence of an intrapelvic solid tumour is of utmost importance. While uterine leiomyomas are common, it is important to adequately counsel a patient who has a pedunculated fibroid regarding the possibility of the mass being of ovarian origin.

As in case 5, pus coming out from the uterus in case of fibroid could be explained by degeneration of the uterine fibroid which is a common complication of fibroid fig. 5. Degeneration can occur when a fibroid outgrows its blood supply, leading to tissue death and potential infection due to the necrotic tissue becoming a site for bacterial growth. This can manifest as severe abdominal pain, fever, and sometimes bleeding, particularly if the degeneration is "red degeneration" which often happens during mid-second trimester of pregnancy. Degeneration is described as hyaline which is most common, followed by myxomatous, calcific, cystic, fatty, red which is usually found only during pregnancy, or necrotic (Munro, et al, 2019). Although patients are often concerned about cancer in fibroids, sarcomatous change occurs in less than 1% of patients (Munro, et al, 2019). The increase in the size of fibroid as a result of hyaline or cystic degeneration is presumed to result from accumulation of extracellular matrix. Although the precise pathogenesis for degeneration of fibroids in postmenopausal women remains unclear, excessive production of growth factors like epidermal or insulin-like growth factor, from the fibroid might explain this condition. Although fibroids usually have a characteristic sonographic appearance, degenerating fibroids can have variable patterns and may pose a diagnostic challenge. A uterine leiomyoma with extensive cystic degeneration can masquerade as an ovarian tumour. MRI may be helpful in complicated cases but should not be used indiscriminately. Hysterectomy may be considered for red degeneration of

uterine fibroid in non-pregnant women, depending on their desire for future fertility, while conservative management is the standard of care in pregnancy.

Other atypical symptoms of leiomyoma may be a protruding vaginal mass with uterine inversion found in cases of submucosal large polypoidal fibroids. Rarely, large subserosal fibroids may irritate the vagus or phrenic nerve causing hiccups. Pruritus with multiple raised skin lesions on the limbs is unusual and is the only symptom of piloleiomyoma. Uterine myoma may coexist with piloleiomyoma. Intra-abdominal haemorrhage is an exceedingly rare manifestation. The aberrant vascular network that feeds subserosal uterine fibroids produce superficial vessels that are weak and prone to rupture. The specific cause of rupture of these superficial vessels remains unelucidated. Trauma, violent coitus, motor vehicle accidents, contact sports, defecation, or pregnancy may provide a reasonable explanation for this rare occurrence. Disseminated peritoneal leiomyomatosis (DPL) is a rare benign disease of unknown aetiology, mimicking disseminated malignancy and affecting women of reproductive age. Although leiomyomas are smooth muscle tumours common to the uterus, unusual growth patterns may occur, leading to three groups of primary neoplasms: intravenous leiomyomatosis, benign metastasising leiomyomas and disseminated peritoneal leiomyomatosis (Vaquero, et al, 2009). Patients with peritoneal leiomyomatosis may present with ascites, peritoneal thickening, and peritoneal or omental nodules, a constellation of signs and symptoms that mimics metastatic ovarian or peritoneal carcinoma. Fibroids have the propensity to attain large sizes that may be comparable to a gravid term uterus. The location and size of fibroids may render them immobile in the pelvis, causing them to compress critical structures such as the bowel, ureter, pelvic venous complexes, and even nerves, leading to bowel obstruction, obstructive uropathy and compressive neuropathy. Obstructive uropathy occurs as a spectrum of hydroureter, hydronephrosis and acute urinary retention, as seen in case 1 and case 5 fig. 1 and fig. 5 respectively.

V. CONCLUSION

Uterine fibroids cause significant morbidity in affected women by causing varied symptoms and clinical manifestations. Awareness of both typical and atypical symptoms of leiomyoma aids in the early diagnosis of these rare fibroid presentations and allows for appropriate counselling of patients. Imaging tools such as CT and MRI can be helpful when diagnosis becomes difficult. There is a risk of compromised function of adjacent organs and higher rates of surgical complications if the fibroid continues to grow. Atypical presentation in terms of clinical manifestation and location of fibroid causes difficulty in diagnosis and thereby challenge during surgery. Explicitly knowing the structures in the pelvis and their anatomical relations with one another helps in delineating the anatomy of vital structures during surgery, thereby causing reduced risk of injury to vital structures, reduced blood loss, reduced duration of surgery and thereby reduced mortality and morbidity. Early diagnosis facilitates prompt treatment in the form of Medical management, Myomectomy when the uterus is still small, thereby preserving fertility or Hysterectomy if conception is not desired.

REFERENCES

Berek and Novak's GYNECOLOGY south south asian edition, topic- fibroid, page no-227

Cervical fibroid: A diagnostic dilemma and operative challenge – one year study - IJOGR https://search.app/k7EZ4vYWocahDKwK6

Kalogiannidis l, Stavrakis T, Dagklis T, et al. A clinicopathological study of atypical leiomyomas: benign variant leiomyomas or smooth muscle tumor of uncertain malignant potential. Oncol lett 2016;11:1425-

Leppert PC, Catherino WH, Segars JH. A new hypothesis about the origin of uterine fibroids based on gene expression profiling with microarrays. Am J Obstet Gynecol 2006;195(2):415–420.

Leung SW, Yuen PM. Ovarian fibroma: a review on the clinical characteristics, diagnostic difficulties, and management options of 23 cases. Gynecol Obstet Invest 2006;62:1–6. 10.1159/000091679 [DOI] [PubMed] [Google Scholar]

Munro MG, Critchley HOD, Fraser IS; FIGO Menstrual Disorders Committee: The two FIGO systems for normal and abnormal uterine bleeding symptoms and classification of causes of abnormal uterine bleeding in the reproductive years: 2018 revisions [published correction appears in *Int J Gynaecol Obstet*. 2019 Feb;144(2):237]. *Int J Gynaecol Obstet* 143(3):393-408, 2018. doi:10.1002/ijgo.12666

N Acharya S Singhal M Agrawal N Singh N Verma Lantern on Dome of St. Paul's Cathedral - An Apt Metaphor for a Challenging LeiomyomaJ Midlife Health20201131814

S Mendiratta S Dath R Mittal S Dath M Sharma RN Sahai Cervical fibroid: an uncommon presentationInt J Reprod Contracept Obstet Gynecol20176941613

Saini A, Gothwal M, Singh P, Yadav G. Utero-ovarian ligament fibroid-an unusual location of extrauterine fibroids. Int J Reprod Contracept Obstet Gynecol. 2020;9(12):5188. [Google Scholar]

SG Vitale F Sapia AMC Rapisarda G Valenti F Santangelo D Rossetti Hysteroscopic morcellation of submucous myomas: A systematic reviewBiomed Res Int20172017684825010.1155/2017/6848250

SK Laughlin-Tommaso GK Hesley MR Hopkins KR Brandt Y Zhu EA Stewart Clinical limitations of the International Federation of Gynecology and Obstetrics (FIGO) classification of uterine fibroidsInt J Gynaecol Obstet201713921438

Song JY, Rotman C, Yordan EL. The broad ligament fibroid. In: Moawad NS, ed. Uterine Fibroids 2018. Springer, Cham; 2017:217-234. [Google Scholar]

Su W. H., Lee W.L., Cheng M.H., Yen M.S., Chao K.S., Wang P.H. Typical and atypical clinical presentation of uterine leiomyomas. J Chin Med Assoc JCMA. 2012 Oct;75(10) :487- 493. Doi: 10.1016/j.jcma.2012.07.004 [DOI] [PubMed] [google Scholar]

Uterine fibroid or ovarian fibroma: importance of comprehensive preoperative consent-taking to include unexpected findings with management implications - PMC https://search.app/apAvDucqnRawQwXZA

Vaquero M.E., Magrina J.F., Leslie K.O. Uterine smooth-muscle tumors with unusual growth patterns. J. Minim. Invasive Gynecol. 2009;16(3):263–268. doi: 10.1016/j.jmig.2009.01.013. [DOI] [PubMed] [Google Scholar]

Vyas P.S., Kim S.W., Castellano J. M., Bal J.K. Plewniak K.M. Uterine fibroid-induced compressive neuropathy of lumbar plexus and obturator nerve. CRSLS MIS Case Rep SLS. 2023 Nov 6;10(4) doi:10.4293/CRSLS.2023.00034 [DOI] [PMC free article] [PubMed] [Google Scholar]

Whiteman MK, Hillis SD, Jamieson DJ, et al. Inpatient hysterectomy surveillance in the United States, 2000–2004. Am J Obstet Gynecol 2008;198(1):34.e1–e7.