

Article

Habitual abortion in Hansen's morbus

*Ismi Mulya Atfi¹**¹*Andalas University Hospital, Padang*

SUBMISSION TRACK

Received: September 22, 2023

Final Revision: December 03, 2023

Available Online: December 31, 2023

KEYWORDS

Hansen's morbus , pregnancy, habitual abortion

CORRESPONDENCE

E-mail: ismimulyaafiti@gmail.com

A B S T R A C T

Based on WHO data, Indonesia is one of the countries contributing around 10,000 cases of Hansen's morbus 2019. Hansen's morbus, or leprosy, is a chronic bacterial infection (*Mycobacterium leprae*) that attacks skin tissue, peripheral nerves, and the respiratory tract. Hansen's disease can occur during pregnancy and worsen during pregnancy. Pregnancy causes a relative decrease in cellular immunity. This can be explained because immunosuppression occurs during pregnancy. Pregnancy is dangerous for women with Hansen's morbus . This case study describes a case of habitual abortion with Hansen's morbus . The patient had a history of Hansen's morbus and had discontinued the medication. During pregnancy, the patient never underwent examination and treatment for Hansen's morbus. So, the patient experiences the habit of abortion. For this reason, it is necessary to carry out good treatment for pregnant women with Hansen's disease so that the mother and fetus receive appropriate treatment.

I. INTRODUCTION

Hansen's morbus is a neglected tropical disease (NTD) that still occurs in more than 120 countries, with more than 200,000 new cases reported yearly. 2019 data shows Brazil, India, and Indonesia reported more than 10,000 new cases.(1) Hansen's morbus disease can occur during pregnancy and worsen during pregnancy.(2) Pregnancy causes a relative decrease in cellular immunity. This fact is explained by physiological immunosuppression in pregnancy, especially in the third trimester and the postpartum period.(3)

Immunosuppression in pregnancy allows Mycobacterium leprae to multiply, which can trigger or release the disease, thereby causing permanent nerve damage.(4) Without treatment, Hansen's morbus 's disease can permanently damage the skin, nerves, limbs, and eyes. Physical and neurological damage may not be repaired even after healing.(2) Type 1 reactions (reversal reactions) occur more often in the postpartum period, when cellular immunity is re-formed, while type 2 reactions (erythema nodosum leprosum/ENL) dominate during pregnancy and breastfeeding, and the risk of recurrence increases during pregnancy.(3)

Babies have a high potential for contracting Hansen's morbus from their mothers through skin-to-skin contact or transmission via droplets, especially if they do not receive treatment for Hansen's morbus .(5) Early detection of Hansen's morbus disease during pregnancy is essential for appropriate clinical management and treatment of pregnant women.(3) Women should be advised to undergo antenatal care (ANC) if pregnant. If pregnancy occurs, antenatal care and monitoring for Hansen's morbus must be carried out in every pregnancy. Termination of pregnancy, surgical or medical, is inadequate for preventing pregnancy-related neuritis.(1)

II. CASE ILLUSTRATION

A 22 year old female patient was referred from the regional general hospital to the central public hospital with habitual abortion and Hansen's morbus. The study showed that the woman experienced her first abortion in October 2022 at 9 weeks gestation. The second abortion occurred in June 2023 at 10 weeks' gestation. The patient was first diagnosed with Hansen's morbus in 2019 with the results of a biopsy of Hansen's morbus type Lepromatous leprosy (LL). The patient underwent routine treatment for Hansen's morbus for 1.5 years at the Central General Hospital until 2022. In August 2023, the patient started treatment for Hansen's morbus again. The patient did not have a history of diabetes mellitus heart, lung, and kidney hypertension. No family members have a history of hereditary disease and Hansen's morbus. However, in the patient's environment, 1 person in the local community had a history of Hansen's disease and had died. The physical examination results showed that the general condition and vital signs were within normal limits. On the extremities, there are lesions on both arms, thighs, and legs in figure 1. On the lower back are erythema papules, hyperpigmented macules, and nodules, accompanied by hypesthesia. The results of the anatomical pathology examination showed that the piece of skin tissue consisted of the epidermis and dermis. The dermis stroma consists of connective tissue stroma containing lymphocyte cells, plasma cells, perivascular and periadnexal foamy histosis. PMN leukocyte cells were also visible. There appears to be a Grenz zone area in the pailla dermis in figure 1.

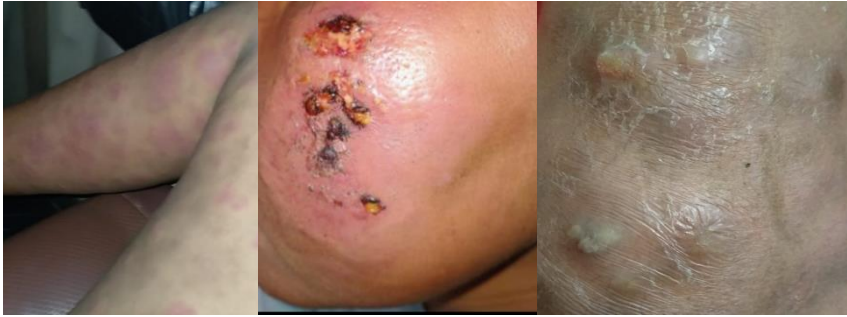

Figure 1 lesions on the extremities and face

The biopsy results showed a microscopic picture consistent with Hansen's morbus LL. On ultrasound examination, there were no cystic or myoma images. The patient has received therapy with clindamycin 2x300 mg, mefenamic acid 2x500 mg, Na fusidate cr 2% 2x1 in biopsy wounds, prednisone tab 1x40 gm in the morning after meals (week 1-2), lansoprazole 1x1, vitamin b complex 1x1, zinc 1x20 mg.

III. DISCUSSION

Pregnancy is associated with increased Hansen's morbus disease, disease worsening, or reversal reactions. This fact is explained by physiological immunosuppression in pregnancy.(3) Immunosuppression during pregnancy is physiological so the fertilized egg, which later becomes a fetus, is not rejected because its genetic makeup (50% of each parent) is incompatible with the mother's. Immunosuppression causes new cases of Hansen's morbus to become apparent in pregnant women who have recovered, showing recurrence and reactivation.(6)

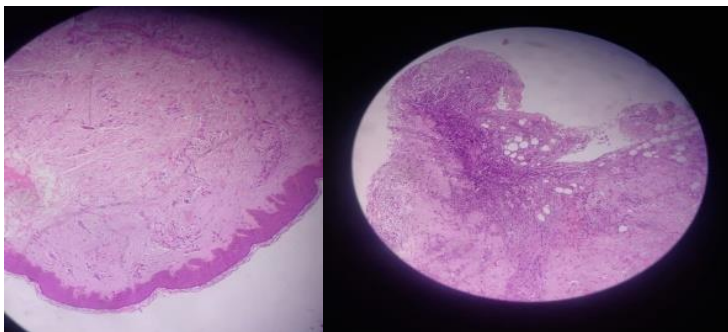


Figure 2 Microscopic picture of Hansen's morbus type LL

The disease manifests generally through skin lesions and peripheral nerve involvement. Hansen's morbus is diagnosed by finding at least one of the following main signs, namely loss of sensation in the skin, patches (hypopigmentation) or redness; thickened or enlarged peripheral nerves, accompanied by loss of sensation and weakness of the muscles innervated by these nerves; Microscopic finding of bacilli in skin gap smears.(1) In some cases, nerve lesions occur early, causing impaired peripheral nerve function (often painlessly). Mucosal lesions of the nasal passages and oropharynx can cause nasal congestion, mild epistaxis, and hoarseness.(7)

The currently recommended treatment consists of three drugs, namely dapsone, rifampin, and clofazimine. The combination is referred to as multi-drug therapy (MDT). The duration of treatment is six months for PB and 12 months for MB cases. Multi-drug therapy kills the pathogen and cures the patient. Early diagnosis and prompt treatment can help prevent

disability.(1) Multi-drug therapy in standard therapy is the treatment of choice for pregnant women and is not associated with an increased risk of miscarriage or congenital abnormalities.(3) In general, patients with Hansen's morbus disease can experience pregnancy well. However, active and dimorphic lepromatous type subgroups have an increased incidence of obstetric complications and infection. (8)

Pregnancy is dangerous for women with Hansen's morbus . In the third trimester, this disease is most dangerous when infection can cause adverse obstetric and fetal effects, such as low birth weight, prematurity, exfoliative dermatitis in newborns, and erythema nodosum in pregnant women.(9) Skin and nerve examinations to determine the presence of new Hansen's morbus, reactivation, or exacerbation of Hansen's morbus should be carried out at the first visit to ANC, 3 months of pregnancy, and 2 years postpartum. A standard body chart showing front and rear views is useful. Old Hansen morbus lesions may be noted in black, and new lesions or ENLs in red. If possible, a slit-skin smear examination for Bacteriological Index (BI) and Morphological Index (MI) should be performed from active lesions. Biopsies should be performed every 3 months from the second trimester until 6 months postpartum from active skin lesions or the buttocks.(6)

Early detection and appropriate treatment of Hansen's disease are crucial to reducing transmission and lifelong disability. Comprehensive treatment for these patients requires coordination of care with other healthcare professionals to address the multiple sequelae of Hansen's morbus (dermatological, neurological, physical/occupational rehabilitation, and psychosocial).(10) Each clinical assessment is an ideal opportunity to deliver health education, including how to perform daily examinations of non-sensitive hands and feet, ensure skin remains moisturized, and go to the hospital immediately if an injury occurs.(6)

IV. CONCLUSION

Immunosuppression causes new cases of Hansen's morbus to become apparent in pregnant women who have recovered, showing recurrence and reactivation. Skin and nerve examination to determine the presence of new Hansen's disease, reactivation, or exacerbation of Hansen's disease should be carried out at the first ANC visit.

REFERENCES

- World Health Organization (WHO). Leprosy [Internet]. WHO. 2023. Available from: <https://www.who.int/news-room/fact-sheets/detail/leprosy>
- Ozturk Z, Tatliparmak A. Leprosy treatment during pregnancy and breastfeeding: A case report and brief review of literature. *Dermatol Ther.* 2017;30(1):1–2.
- Lourenc AC. Therapeutic approach of leprosy in pregnancy. *J Am Acad Dermatol.* 2013;68(4):AB125.
- Lyde CB. Pregnancy in patients with hansen disease. *Arch Dermatol.* 1997;133(5):623–7.
- Gimovsky AC, Macri CJ. Leprosy in pregnant woman, United States. *Emerg Infect Dis.* 2013;19(10):1693–4.
- Duncan E. *Leprosy in Pregnancy.* Springer, Milano; 2012. 331–340 p.
- Mehta S, Grover A. *Infections and Pregnancy.* Infections and Pregnancy. 2022. 1–685 p.
- Maurus JN. Hansen's disease in pregnancy. *Obs Gynecol [Internet].* 1978;52(1):22. Available from: <https://pubmed.ncbi.nlm.nih.gov/683625/>
- Fatola C, Venyo A-G, Venyo L-G, Lindsay Maloney D. Leprosy in pregnancy – a review of the literature. *Hamdan Med J.* 2015;8(1):83.
- Maymone MBC, Venkatesh S, Laughter M, Abdat R, Hugh J, Dacso MM, et al. Leprosy: Treatment and management of complications. *J Am Acad Dermatol [Internet].* 2020;83(1):17–30. Available from: <https://doi.org/10.1016/j.jaad.2019.10.138>