

Article

Breasts and Lymphatic Tissue ; A Literature Review

Muhammad Iqbal,¹ Wirsma Arif Harahap,²

¹Department of Anatomy, Faculty of Medicine, Andalas University, Dr. M. Djamil Central General Hospital, Padang City, Indonesia

²Department of Surgery, Faculty of Medicine, Andalas University, Dr. M. Djamil Central General Hospital Padang City, Indonesia

SUBMISSION TRACK

Received: July 2 2020

Final Revision: November 26 2020

Available Online: 6 December 2020

KEYWORDS

Breast, Lymphatic flow

CORRESPONDENCE

Phone: 081318884229

E-mail: dr.m.iqbal92@gmail.com

A B S T R A C T

The breasts begin to grow from the sixth week of the embryo in the form of ectodermal thickening along the milk line that lies from the axilla to the middle of the groin (inguinal). The blood supply comes from the internal mammary artery, which is a branch of A. subclavian. Additional bleeding originated from A. axillary through the branches of A. thoracic lateral, A. thoraco dorsalis, and A. thoraco acromialis. The return of blood through the veins follows the passage of the artery to the internal mammary V. and the axillary vein branches to the superior V. kava. Lymph capillaries are located under the epidermis with a diameter between 20 and 70 mm. Lymphangion, as a pacemaker is limited by valves and lymphatic endothelial cells, will initiate an intrinsic pulsation of lymph fluid flow. Extrinsic factors such as contraction of the skeletal muscles, massage, increased hydrostatic pressure by postural gravity can also affect the lymphatic flow rate.^{5,6} These lymphatic vessels run on the lateral side of the upper arm, parallel to the cephalic vein and drain into the supraclavicular nodes.⁴ The LVC is an important anatomical structure for the physiology of vascular lymph node transplantation (VLNT).⁸ Lymph vessels in the upper limb travel axially from the fingers to the back of the hand and make direction to the elbow, travel to the anteromedial area at the top of the arm and connect to the axillary lymph nodes in the lateral area. An alternative route directly to the supraclavicular node can be identified. These lymphatic vessels run on the lateral side of the upper arm, parallel to the cephalic veins and drain into the supraclavicular nodes.⁴ The LVC is an important anatomical structure for the physiology of vascular lymph node transplantation (VLNT).⁸ An alternative route directly to the supraclavicular node can be identified. These lymphatic vessels run on the lateral side of the upper arm, parallel to the cephalic veins and drain into the supraclavicular nodes.⁴ An alternative route directly to the supraclavicular node can be identified. These lymphatic vessels run on the lateral side of the upper arm, parallel to the cephalic veins and drain into the supraclavicular nodes.

Breast Anatomy

The breasts begin to grow from the sixth week of the embryo in the form of ectodermal thickening along the milk line that lies from the axilla to the middle of the groin (inguinal). During its development the growth in the milk line becomes rudimentary and settles only in the chest area. In women the breast glands become functional at puberty and respond to estrogen. The breast glands reach the peak of development during pregnancy and function to produce milk after delivery. Furthermore, the breast glands involute at menopause. ¹

Boundaries of Breast Anatomy

- Superior limit : rib II or rib III (or subclavicular line)
- Inferior limit : costal VI or VII (submammary fold line)
- Medial : parasternal line
- Lateral : anterior axillary line

At the time of the mastectomy surgery is very important for the recognition of this breast border. ¹

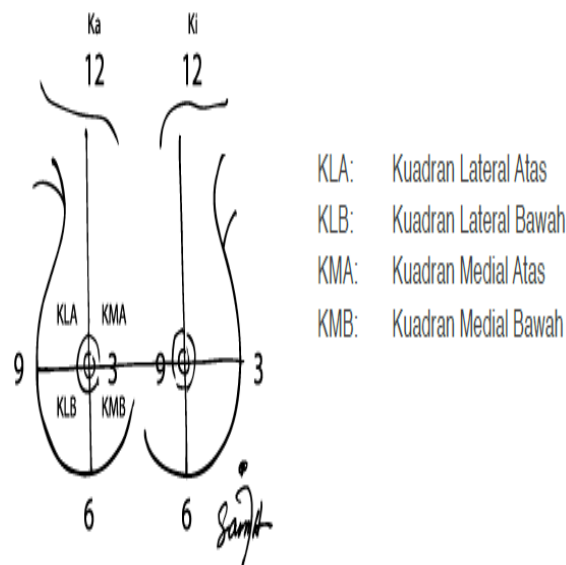


Figure 1. Image of Breast Quadrant

Bleeding and Breast Lymphatic Flow

The blood supply comes from the internal mammary artery, which is a branch of A. subclavian. Additional bleeding originated from A. axillary through the branches of A. thoracic lateral, A. thoraco dorsalis, and A. thoraco acromialis. The return of blood through

the veins follows the passage of the artery to the internal mammary V. and the axillary vein branches to the superior V. kava (6).

1. Axillary lymph nodes (KGB) are the main route of regional spread of primary breast cancer. Axillary groups are grouped into:

- a) the apical or subclavicle group,
- b) axillary vein group,
- c) interpectoral groups or Rotter's,
- d) scapular group,
- e) the central group.

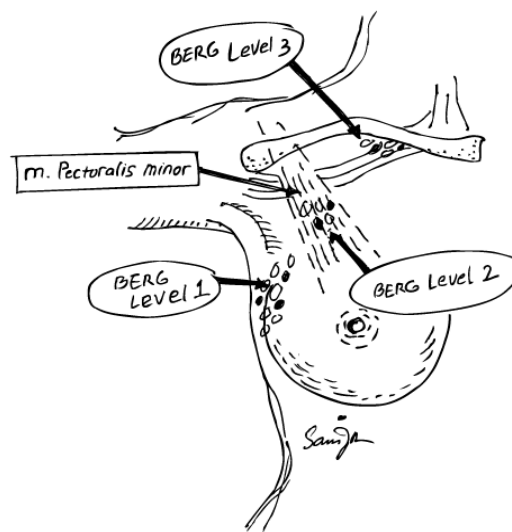


Figure 2. Image of Lymph according to Berg

Anatomy of Lymph Vessels and Lymphatic Tissues³

Lymph vessels

Lymph capillaries start out as dead ends. These capillaries are different from blood capillaries because these capillaries can absorb protein and large particles from the spaces in the tissue, while the fluid that is absorbed by blood capillaries is a fluid of homogeneous inorganic salts and sugars.

Lymph from capillary matting travels into larger collecting vessels. At strategic locations along the passage of these vessels are small, oval masses of lymphatic tissue, called lymph nodes. The direction of lymph flow is determined by the lymph vessel valves. Lymph vessels tend to travel along blood vessels. At the extremities, the superficial lymph vessels of the skin and subcutaneous tissue tend to follow the superficial veins. The deep lymph vessels follow the deep arteries and veins.

Thoracicus Ductus

The thoracic duct begins below in the abdomen at the level of the II lumbar vertebra as a dilated pouch, the cisterna chyli (Figure 3). The thoracic duct runs upward through the hiatus aorticus diaphragm, to the right of the aorta descending. Gradually the ductus crosses the middle plane behind the esophagus and reaches the left edge of the esophagus at the level of the IV thoracic vertebra. Then the ductus runs upward along the left edge of the esophagus to enter the base of the neck. Here the ductus bends laterally behind the carotid sheath (containing the common carotid artery, vagus nerve, and jugular vein intema), and bends downward and crosses the subclavian artery to reach the base of the left brachiocephalic vein.

Ductus Lymphaticus Dexter

Truncus jugularis dexter, truncus subclavius dexter, and truncus bronchomediastinalis dexter which drain lymph from the right side of the head and neck, respectively, the right superior extremity, the right side of the thorax, can combine to form the ductus lymphaticus dexter (Figure 3). This ductus if there is about 1.3 cm long and empties into the base of the right brachiocephalic vein. In addition, each truncus can lead to large veins at the base of the neck.

Lymphatic Tissue

Lymphatic tissue has a woven base of fibers and reticular cells. Within the reticular webbing space are a large number of lymphocytes, which may and may not be associated with plasma cells. Lymphatic tissue is found in the following forms: lymphaticus nodes, thymus, spleen and lymphoidei nodules.

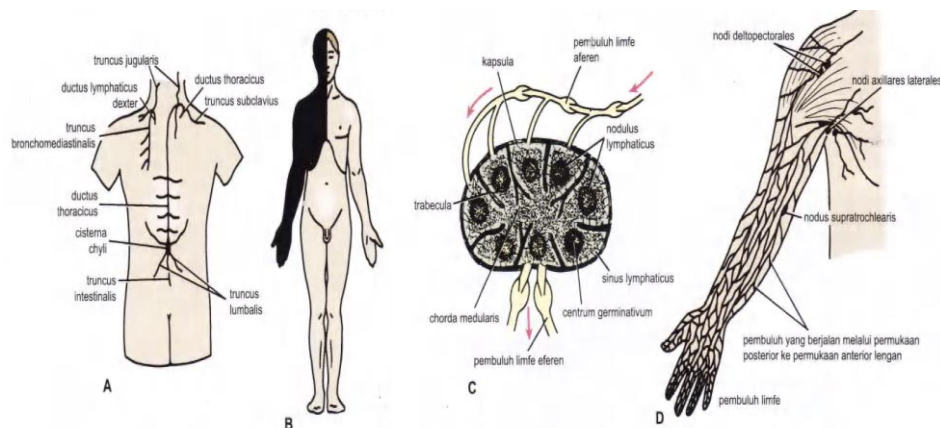


Figure 3. A. Ductus thoracicus and ductus lymphaticus dexter and its main branches. B, The area of the body that drains lymph fluid to the thoracic duct (white) and

ductus lymphaticus dexter (black). C. General structure of the lymph nodes (node lymphaticus). D, vessels and lymph nodes of the superior extremity

2. The internal mammary group.

Located retrosternal in the inter-rib space in the parasternal region, along the internal mammary vasa.

Nodus Lymphaticus

Lymphaticus nodes can be found throughout the body and are located along the passage of the lymph vessels (Figure 3). They are oval or kidney-like in shape and vary in length from a few millimeters to 2 cm. Lymphaticus nodes are usually found in clusters and are associated with lymphatic flow from certain areas or organs. Each lymphaticus node is covered with a strong fibrous capsule, which forms a number of fibrous partitions within the node called trabeculae. Depending on the trabecula there is a three-dimensional webbing of the reticular fibers.

Head and Neck Lymph Stream

Nodi lymphoidei in the head and neck region (Figure 4) are arranged in a neck group extending from under the chin to the back of the head and a deep vertical terminal group which is embedded in the carotid sheath in the neck region.

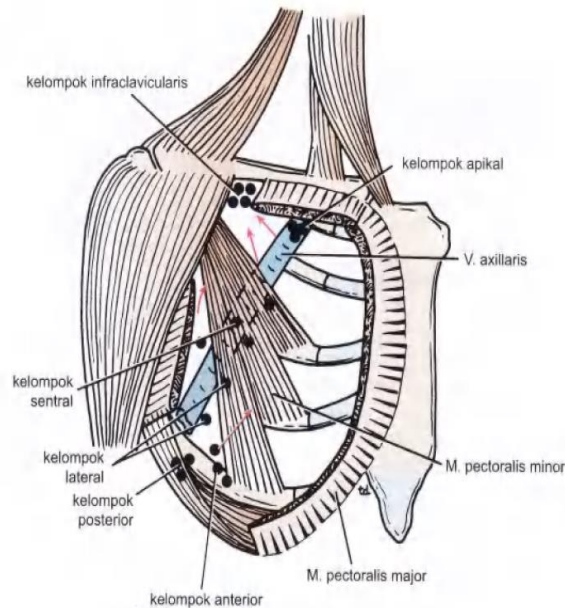
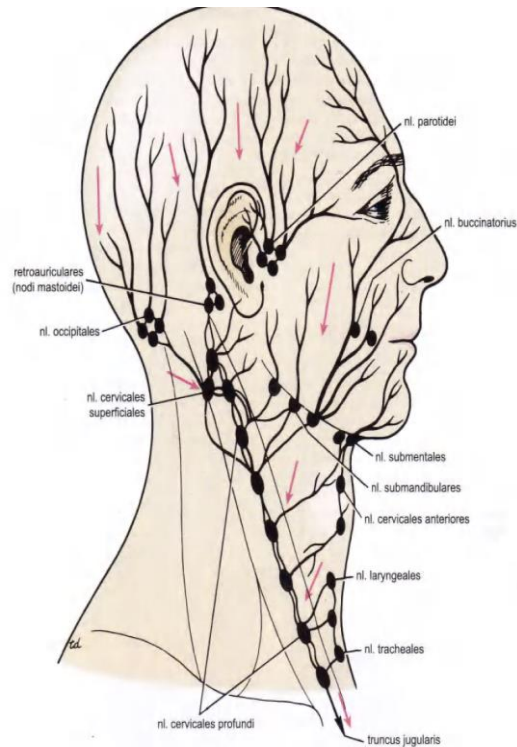
Extremity Lymph Flow

The superior extremity lymph vessels are arranged in superficial and deep groups. The superficial lymph vessels rise above the extremities in the superficial fascia and follow the superficial veins. The deep lymph vessels lie deep against the deep fascia and follow the veins and deep arteries. All lymph vessels of the superior extremity eventually lead to the lymph nodes which are located in the axilla.

Nodi Lymphoidei Axillares

Nodi lymphoidei axillares (Figure 5) drain lymph from all over the superior extremity. In addition, these lymphoid nodes receive lymph from the lateral quadrant of the breast and superficial lymph vessels from the thoracoabdominal wall above the umbilicus. Nodi lymphoidei axillares number 20-30 and are located as follows:

1. **Nodi lymphoidei anteriores (pectorales):**lies along the lower edge of the pectoralis minor musculus behind the pectoralis major, in other words behind the anterior wall of the axilla. This group accommodates lymph from the lateral quadrant



Figures 4 and 5. Head and Neck Lymph Streams; Various groups of nodi lymphoidei in the axilla mamma and superficial lymph vessels of the thoracoabdominal wall above the umbilicus.

2. **Nodi lymphoidei posteriores (subscapulares):**located in front of the subscapularis muscle on the posterior wall of the axilla. This group receives lymph vessels from the back, down as far as the iliac crista.
3. **Nodi lymphoidei laterales:**located along the medial side of the axillary vein. This group received most of the lymph vessels of the superior extremity (except for the superficial lymph vessels from the lateral side; see infraclavicular nodi).

4. **Nodi lymphoidei centrales:** located in the axilla center in the axilla fat. This group received lymph from the three groups above.
5. **Nodi lymphoidei infraclaviculares (deltopectorales):** This group is located in the sulcus between the deltoid and pectoralis major muscles along the cephalic vein. This group receives superficial lymph vessels from the lateral side of the hand, forearm, and upper arm; Lymph vessels follow the cephalic veins.
6. **Nodi lymphoidei apicales** This group is located at the apex of the axilla on the lateral edge of the rib I. This group receives lymph from all its axillary lail glands. The apicales lymphoidei drain their lymph into the subclavius truncus, which on the left empties into the thoracic duct, and on the right into the dexter lymphaticus duct.

Mammaria Gland Lymph Flow

The lateral quadrant drains lymph into the nodi lymphoidei axillares anteriores (Figure 6).

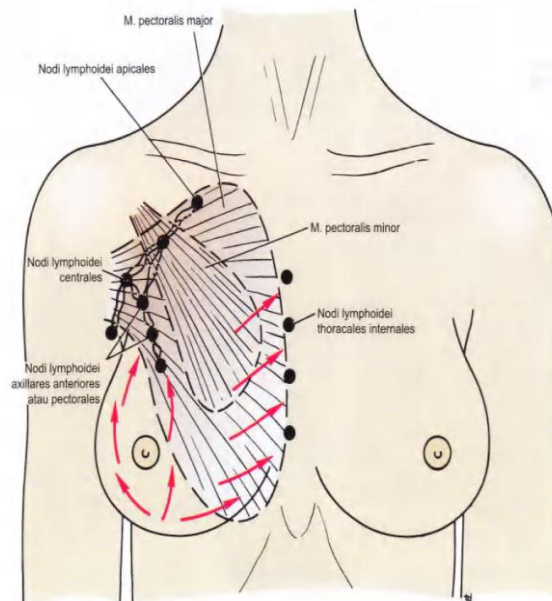
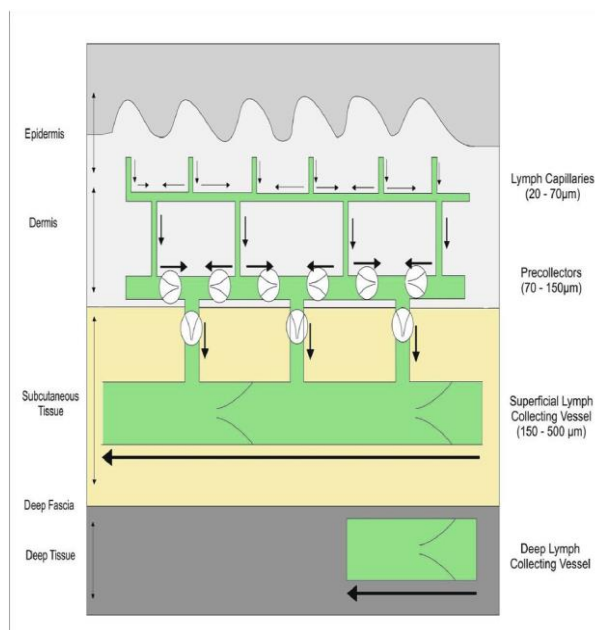


Figure 6. Mammae Lymph Flow



Picture. 7. Anatomy of the lymphatic system. Lymph flows from lymphatic capillaries in the dermis to the precollecting lymphatic vessels, and to the collecting lymphatic vessels; goes to the proximal and finally drains into the venous circulation at the corner of the vein through lymph node filtration.

The medial quadrant drains lymph into the lymphoid nodi along the internal thoracic artery in the thorax. Several superficial lymph vessels are associated with the same lymph vessels from the other side of the breast and with glands in the anterior abdominal wall. Several lymph vessels drain into the nodi lymphoidei intercostales posteriores in the posterior.

Anatomically, the structure of the lymphatic vessels is divided into capillaries, pre-collectors, and collecting vessels.⁴ Lymph capillaries lie beneath the epidermis with a diameter of between 20 and 70 mm. They do not have valves and are only structured by a single layer of lymphatic endothelial cells (LEC). Vessel capillaries are highly permeable because of the connections between the LECs by fibrous structures called retaining filaments which are loose and in an overlapping pattern. The increased pressure on the interstitial tissue opens endothelial cells outwards allowing interstitial fluid to enter the lumen. After entering the caFigure 7 illustrates a schematic of the lymphatic system. The walls are made up of three layers: LEC, smooth muscle cells (SMC), and collagen fibers. The lymphatic vessels do not have a centralized pumping system such as the arterial and venous systems and the movement of lymphatic fluid is stimulated by intrinsic and extrinsic factors. Lymphangion as a pacemaker which is limited by valve and LEC, will initiate the intrinsic pulsation of lymph fluid flow. Extrinsic factors such as contraction of the skeletal muscles, massage, increased

hydrostatic pressure by postural gravity can also affect the lymphatic flow rate.^{5,6} Lymph collectors are categorized into superficial vessels and in relation to deep fascia. Usually,

The lymphatic vessels will eventually drain into the lymph nodes before connecting to the veins. Fluid enters the lymph nodes by afferent vessels in the subscapular sinuses and exits through efferent vessels. More importantly, lymph nodes may contain lymphaticovenous communication (LVC) which can drain lymph fluid from surrounding tissues into the nodes and into intranodal veins. The LVC is an important anatomical structure for vascular lymph node transplantation physiology (VLNT).⁸

REFERENCES

1. Purwanto H, Handoyo D, Haryono S, Harahap W. Guidelines for Breast Cancer Management. 2014th ed. Purwanto H, Handoyo D, Haryono S, Harahap W, editors. Jakarta: PERABOI; 2015. 15–21 p.
2. Suzanna E, Rahayu P, Sirait T, Agustina J, Limbong M. Hospital-based Cancer Registration at Dharmais Cancer Hospital 2003-2007. *Indones J Cancer*. 2012; 6.
3. Richard S. Snell. Clinical Anatomy Based on Systems jo A, Liestyawan Y, editors. Jakarta: Medical Book Publishers, EGC; 2007. 264–269 p.
4. ACS. Breast Cancer [Internet]. 2019 [cited 2020 Feb 25]. Available from: <https://www.cancer.org/cancer/breast-cancer/understanding-a-breast-cancer-diagnosis/stages-of-breast-cancer.html>
5. AJCC. Breast. In: Edge S, Byrd D, Compton C, Fritz A, Greene F, Trotti A, editors. *AJCC CANCER STAGING MANUAL*. 7th ed. Chicago: Springer; 2010. p. 347–76.
6. Winer EP, Morrow M, Osborne CK, Harris JR. Malignant Tumors of the Breast. In: DeVita Jr. V, Rosenberg SA, Hellman S, editors. *DeVita - Cancer: Principles and Practice of Oncology*. 6th ed. Lippincott Williams & Wilkins Publishers; 2001.
7. Menen R, Thesome M. Invasive Breast Cancer. In: Feig B, Ching C, editors. *The MD Anderson Surgical Oncology Handbook*. 6th ed. Wolters Kluwer Health; 2018. p. 59–71.
8. Mberto U, Eronesi V, Atale N, Ascinielli C, Uigi L, Ariani M, et al. The New England Journal of Medicine TWENTY-YEAR FOLLOW-UP OF A RANDOMIZED STUDY COMPARING BREAST-CONSERVING SURGERY WITH RADICAL MASTECTOMY FOR EARLY BREAST CANCER A BSTRACT Background We conducted 20 years of follow-up. *N Engl J Med* [Internet]. 2002; 347 (16): 1227–32. Available from: www.nejm.org

